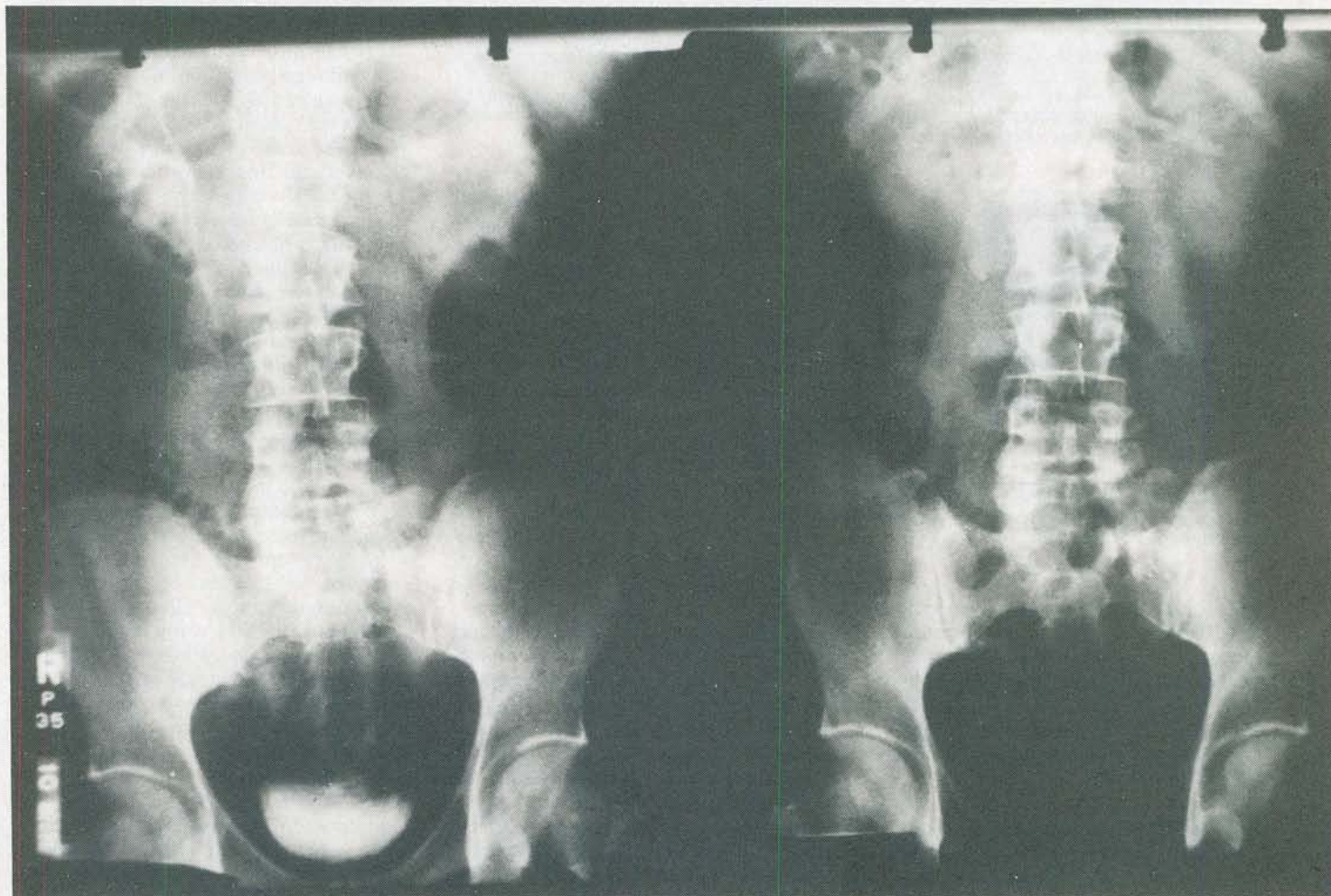


Electronics In Medical Imaging



Various imaging techniques, such as X-rays and CAT scans, are commonly used in medicine. In this article, we'll take a look at those techniques and the role electronics plays in them.

Ray Fish, Ph.D., M.D.

MEDICAL IMAGING IS USED TO DISPLAY the structure and function of the body. It is used to obtain information about the status of a healing fracture, the presence of a tumor, the ability of the kidneys to remove substances from the blood, the presence of bleeding in the head, and the flow of blood through arteries and veins. Electronics has played an important role in medical imaging in the past, and that role is steadily increasing. In this article we will discuss medical imaging techniques such as conventional X-rays, fluoroscopy, linear tomography, computerized tomography, and ultrasound.

X-rays

X-rays are produced when a tungsten target is bombarded by an electron beam

of sufficient energy. In 1895, Professor Roentgen discovered that X-rays were capable of penetrating living tissue and making images of it appear on fluorescent surfaces.

Photographic film itself is relatively insensitive to X-rays. In order to overcome that, the film is placed in a "cassette" that holds a fluorescent screen close to the X-ray film. When struck by X-rays, the fluorescent screen emits light that blackens the film. If an object prevents X-rays from reaching the film and fluorescent screen, the film remains transparent (light) in appearance at such points.

Figure 1 shows the arrangement used to take a conventional X-ray picture. Exposure parameters vary according to the size of the person. A standard chest X-ray

will use an exposure time of about $\frac{1}{40}$ second, an X-ray tube voltage of 120 kilovolts, and a current of 400 milliamperes. The exact exposure time is determined automatically in many systems by an X-ray sensitive detector behind the film and screen. Note that the X-ray beam is divergent; it is cone-shaped and increases in size as it travels from its source. Therefore distances between the film, the patient, and the source of radiation will affect the size of images seen. For that reason, standardized techniques must be used when taking pictures to avoid confusion.

Figure 2 shows a conventional chest X-ray. Air permits the greatest amount of radiation to reach the film cassette. The lungs contain much air, hence they are the darkest area on the X-ray. Decreasing

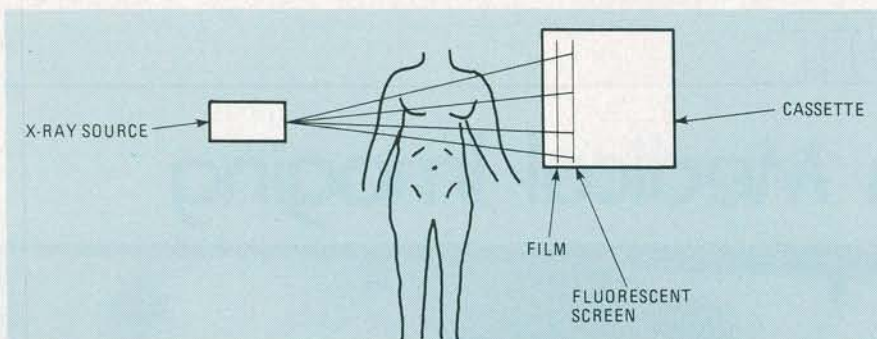


FIG. 1—ROUTINE CHEST X-RAY'S are taken using the arrangement shown. Note that the film is located in a cassette that also has a fluorescent screen.

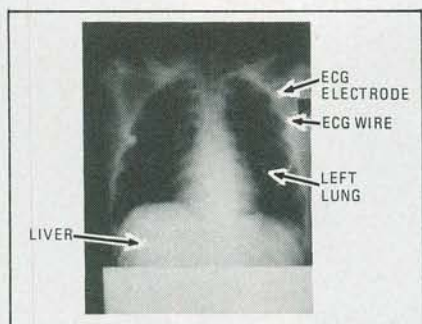


FIG. 2—A CHEST X-RAY. Since air allows the maximum amount of X-rays to reach the film, the lungs show up as a dark area.

amounts of radiation are able to penetrate soft tissues, bone, and metal. All material between the X-ray source and film contributes to the image regardless of the distance of the material from the film. For example, a rib on the front of the chest will be imaged about the same as a rib on the back of the chest.

Tomography

Figure 3 shows a method of obtaining images at a certain depth inside the body. That technique is called conventional tomography and has been in use for many years. In conventional (non-computerized) tomography, the X-ray source and film are moved simultaneously for several seconds as the picture is being taken. The geometry is arranged such that tissue densities at a certain distance from the film will remain in focus at all times during the

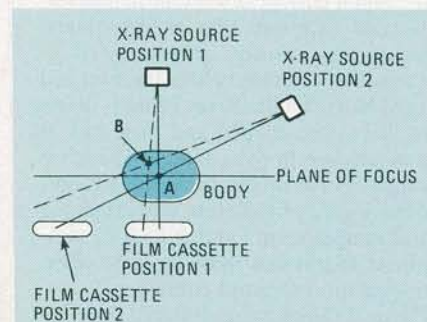


FIG. 3—CONVENTIONAL TOMOGRAPHY. In this technique, the X-ray source and the film cassette move in such a way as to keep all the structures in one plane in focus.

X-ray exposure, while tissue densities in other planes will be smeared broadly across the film. That type of tomography is relatively inexpensive and is useful even though it does not produce as clear an image as computerized tomography. Computerized tomography (which will be discussed below) is more sensitive to small differences in tissue density and has a finer resolution (smaller objects and smaller details can be seen).

Figure 4 compares images obtained by conventional tomography (Fig. 4-a) and conventional X-rays (Fig. 4-b). Different levels in the body are displayed in separate images in conventional tomography, showing detail not visible in a standard X-ray.

It is possible to put substances inside the body that strongly block X-rays. One can inject liquids called contrast agents into arteries, veins, and various body cavities. If placed into an artery, an arteriogram is obtained. Contrast agents injected into a vein will allow an X-ray to be taken that will show the vein, as seen in Fig. 5. Blockage in branches of an artery or vein can thus be seen. Blockages can occur when materials are deposited on the inner wall of an artery. Those form a relatively solid mass called a plaque. That is

especially important when the coronary arteries that supply blood to the heart muscle are involved. People often have chest pain from partial blockage of the coronary arteries. Similarly, partial blockage of the arteries supplying the legs may cause leg pain with walking. Partial blockage of the arteries supplying a kidney can cause high blood-pressure (hypertension). Blockage of arteries and veins can also occur because of blood clots, foreign bodies, or injury.

When a partial blockage of an artery is discovered, surgery can be performed to place a segment of vein in parallel with the blockage. That allows blood to bypass the blockage via the vein. Alternatively, in some cases a balloon can be placed in the partially blocked blood vessel and inflated. The material obstructing the vessel will be compressed into the walls of the vessel. Those techniques permit normal blood flow and cause relief of symptoms. In patients with certain types of coronary artery blockage, coronary bypass surgery is used to prolong life.

The kidneys normally remove many substances from the blood. Contrast agents can be injected into a vein in the arm, a simple procedure. The contrast agent will then travel through the circulatory system and eventually be concentrated and excreted by the kidneys. Kidney X-rays, also called intravenous pyelograms or IVP's can then be taken. The functioning and structure of the kidneys, ureters, and bladder can be studied using an IVP. While many kidney stones will not show on an X-ray, they can be seen in an IVP.

Fluoroscopy

Fluoroscopy is imaging that occurs when X-rays strike a surface that emits light as a result of X-ray exposure. Image intensifiers used in fluoroscopy can increase the amount of light seen and de-

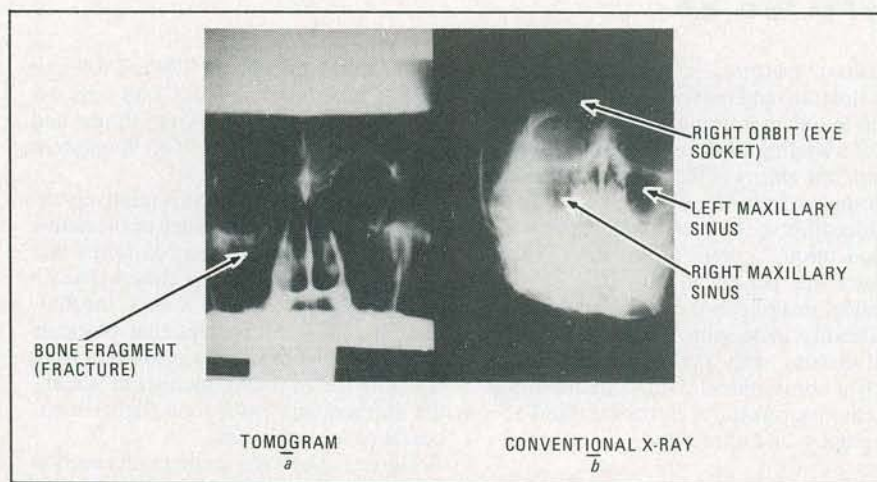


FIG. 4—A BONE FRAGMENT that shows up in the tomogram in a, does not show up in the conventional X-ray shown in b.

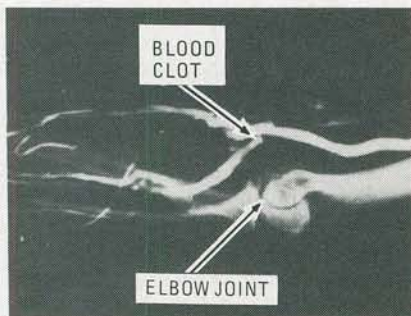


FIG. 5—IN THIS VENOGRAM, dye is injected to help pinpoint the location of a blocked vein.

crease by a factor of 1000 the amount of radiation needed to give a useful image. Image-intensifier tubes have a fluorescent screen that emits light when struck by X-rays. That light causes electrons to be emitted from a light-sensitive surface that is just behind the fluorescent screen. Those electrons are attracted to a second fluorescent screen by a high voltage, producing a brighter image than the one on the first fluorescent screen. The second fluorescent screen may be looked at directly or may be viewed by a television camera.

Use of a television camera permits magnification, image enhancement, image recording, and other image processing to be done by standard video equipment. X-ray images can be stored in a digital memory. It is possible that in the future, most X-rays will be taken with fluoroscopic equipment and be stored on videodiscs or videotape, rather than on large, expensive pieces of film. Thousands of separate X-ray pictures could be recorded on one videodisc or videotape.

Digital subtraction angiography

Digital subtraction angiography is a technique that allows imaging of arteries without injecting contrast material directly into them. Without digital-subtraction techniques, it is necessary to inject a liquid contrast material directly into an artery that is to be imaged. X-rays are taken when the contrast material is in the artery.

If the artery being studied is deep in the body, a catheter must be placed near the artery and the contrast material injected. For example, the renal (kidney) arteries are often examined. That involves placing a catheter near the kidneys by threading it through an artery, such as the femoral artery in the leg. That procedure is uncomfortable, is difficult to perform, and has the risk of complications. Complications include infection or bleeding at the site the artery is punctured. Also, the catheter may knock a plaque off the wall of any artery it passes through (such as the aorta between the groin and the kidney). A plaque knocked loose by a catheter will travel through the blood stream and eventually cause occlusion of a branch of the

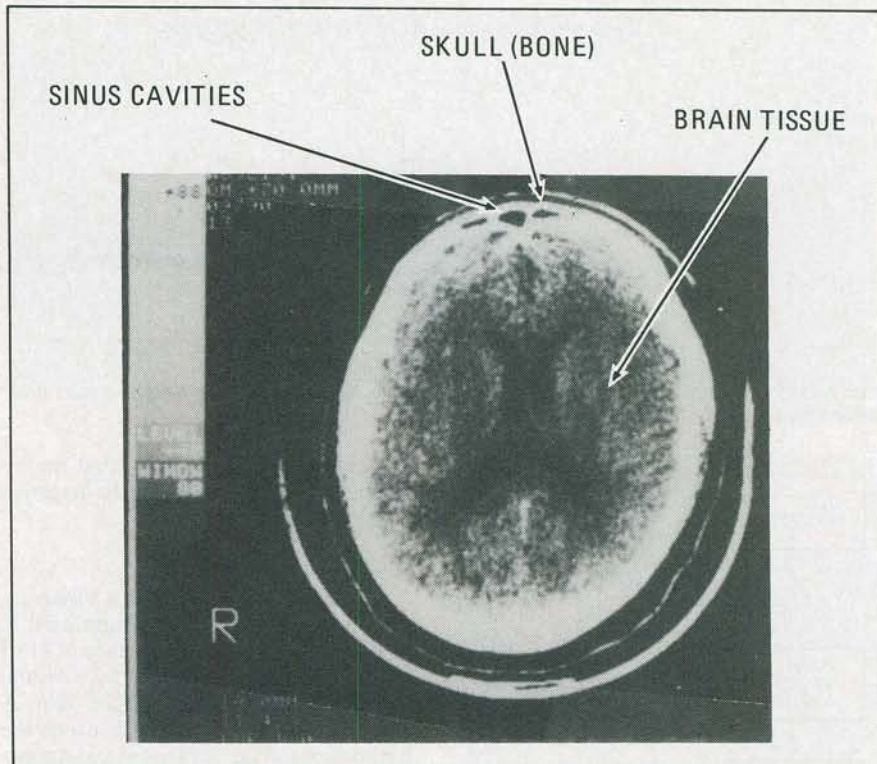


FIG. 6—A COMPUTERIZED AXIAL TOMOGRAPHY (CAT) scan of a human head. One horizontal level is shown here.

artery. That causes a lack of blood in the area supplied by the artery. If that area is in the brain, for instance, the person will have a stroke. Such complications caused by the insertion of a catheter are fortunately infrequent (about 0.1% of cases), but the cost and discomfort of arteriography do affect every patient.

With digital subtraction angiography, the need for an arterial catheter is eliminated. With the subtraction technique, an X-ray image of the area containing the artery of interest is obtained and stored in a digital memory. A contrast agent is injected into a vein in the arm, a simple, relatively safe procedure. A small percentage of the contrast agent will travel to the artery of interest, but not enough to cause an image to form on a plain X-ray. A second X-ray image is taken and stored in digital memory. The first image is then subtracted, point by point, from the second image. Structures that were the same when the two pictures were taken cancel out.

The image remaining is that caused by the circulation of the small amount of dye through the artery during the second picture. An image similar to a standard arteriogram is thus obtained without the cost, discomfort, and dangers of arterial catheterization. If there is movement between the two pictures, the images will not line up properly. Taking multiple pictures before and after the injection and choosing those that give the best image is sometimes done. Digital subtraction an-

giography is of limited use in imaging the coronary arteries because the heart moves about significantly. As digital subtraction angiography equipment becomes more refined and less expensive, it is expected that it will gradually replace conventional arteriography equipment in many applications.

Computerized axial tomography

Computerized axial tomography (CAT) is a technique that can obtain images of slices of tissue a few millimeters thick. That technique is very sensitive to differences in X-ray absorption of tissues. Conventional X-rays and tomograms are incapable of detecting the differences in X-ray absorption of soft tissues and fluids (such as blood, brain tissue, and water). Computerized axial tomography can be used to detect those differences (see Fig. 6).

If surgery is needed to correct bleeding inside the head, the CAT scan will usually show that. Arteriography was necessary to detect bleeding in the head before the CAT scan was available. The arteriography dye was injected into the carotid arteries that supply blood to the head. Arteriography is difficult, expensive, and uncomfortable. The CAT scan is safer than arteriography, without discomfort, and easy to perform. On the other hand, one drawback to CAT scans is that they are still somewhat expensive.

The CAT scan is performed by having one or more sources of X-rays and multi-

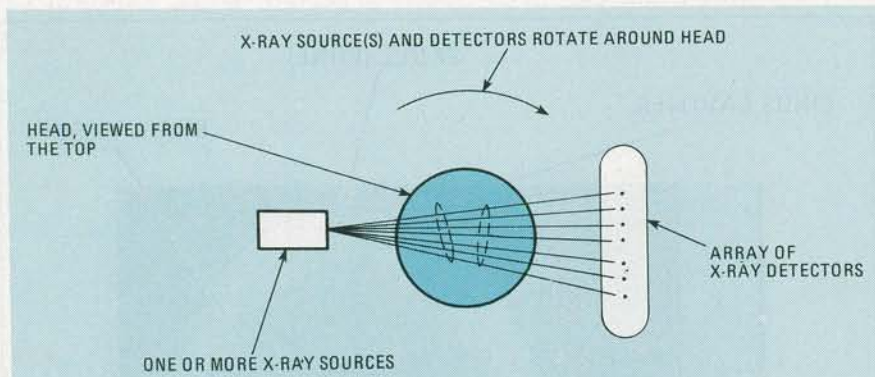


FIG. 7—SET UP USED in computerized axial tomography. Here, one or more X-ray sources rotate around the part of the body being scanned.

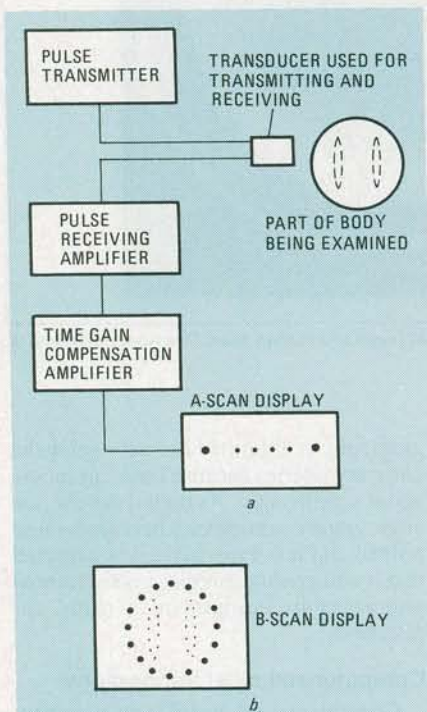


FIG. 8—BLOCK DIAGRAM of the set up used to obtain an ultrasound A-scan is shown in a. A B-scan, which is made up of a series of A-scans, is shown in b.

ple X-ray sensitive transducers positioned around the area to be examined. Figure 7 shows a simplified diagram with just one X-ray source and a few X-ray detectors. The amount of X-ray energy reaching each transducer is accurately measured. The assembly of transducers rotates around the area, taking measurements along many lines that pass through the plane being examined. Tens of thousands of measurements are made. The plane is divided into picture elements (pixels). A computer notes which lines crossed through which pixels and how much energy got through the tissue each line crossed. Having that information, the X-ray density (or the absorption) of each pixel can be calculated. In practice, the calculation of pixel density is too time-consuming, but computers can make approximate solutions and fit them to the

data. Once that task is completed, an image made up of the pixels can be displayed by the computer.

Ultrasound

Ultrasound is sound that is at a frequency too high to hear. Ultrasound used in medicine usually has a frequency of 1 to 5 MHz. Ultrasound is emitted by a crystal transducer that is placed on the skin. A jelly-like material is placed between the transducer and the skin to increase transmission. A portion of the transmitted ultrasound is reflected back to the transducer when an interface between different tissues is met. Thus, after a short pulse of ultrasound is emitted, a series of echoes is received, as shown in Fig 8-a. That tracing is referred to as an A-scan. The strength of individual echoes depends on the differences in mechanical properties of the tissues at each interface. For example, when a pulse crosses the boundary between muscle and blood, about 0.1% of the energy is reflected. The remainder of the energy continues on to image deeper structures.

The attenuation of ultrasound increases with frequency. For most soft body tissues, the attenuation coefficient is about 1 dB/cm/MHz. A structure 5 cm deep in the body will attenuate a 3.5-MHz signal 35 dB. A 10-MHz signal will be attenuated 100 dB. To compensate for the decrease in signal strength with depth, a time (or distance) gain control (TGC) system is used to pre-process the signal from the transducer. Signals received further in time after the transmitted pulse are amplified more. A series of gain switches are present on some ultrasound machine panels so the technician can set the gain at various depths to obtain a picture that continues to show tissue interface reflections despite the attenuation of the signal that occurs due to depth and various intervening structures.

Higher frequencies give a finer picture resolution because it is not possible to resolve structures smaller than about a wavelength in size. The wavelength at 1.5 MHz is about 1 millimeter. Higher frequencies are desirable unless the signal

must travel so deep into the body that it will be attenuated too much. Frequencies up to 15 MHz are used to examine the eye and other small body parts. Frequencies around 3 MHz are used for deep abdominal imaging.

The angle the tissue interface makes with the direction of the ultrasound beam may cause deflection of the beam in another direction. Successive echoes decrease in amplitude because the energy of the ultrasound is absorbed by the tissue as well as being reflected and refracted.

The mechanical properties of air and bone differ from those of soft body tissues so much that, for practical purposes, ultrasound does not penetrate air and bone. That inability to penetrate air and bone obviously limits the use of ultrasound greatly.

Despite significant absorption and refraction, useful images can be obtained using ultrasound. A two-dimensional picture, called the B-scan (see Fig. 8-b), is produced by displaying many A-scans simultaneously. Those are produced using a rapidly vibrating or rotating transducer that emits hundreds of pulses per second. That technique can be used to produce a real-time picture. Alternatively, a storage-type display can be used. In that technique, the transducer is moved manually by a technician and successive images are retained on the display, producing a picture. The quality of the picture that results from that technique can vary greatly because it depends on the skill of the technician.

B-scan ultrasound machines produce images that can be stored in a computer memory. Some commercially available machines have pictures with 16 gray levels. The images can be frozen, magnified, measured electronically, and photographed. A movable dot (cursor) can select an area to be examined for overall movement (such as a heartbeat) or for blood flow.

Some B-scan ultrasound machines have two movable dots (calipers) that can be positioned anywhere on the screen by a joystick. A digital readout of the distance between the two dots is displayed. That is useful for such things as measuring the head size (called the biparietal diameter) of fetuses. The biparietal diameter is related to the age of the fetus. Some ultrasound machines are made specifically for obstetrics. With those ultrasound machines, the heartbeat of a fetus can be monitored, for instance along with other physical data.

The screen containing the B-scan image in some machines will display the patients' name and other data so the photograph will not need further labeling or get mixed up with other patient's records. The patient's name and information about exposure settings is displayed on CAT images in a similar manner.